

UNIVERSITY OF NAIROBI

RETINOBLASTOMA

DR. K. KIMANI

DEPT OF

Introduction

- Primitive embryonic tumor from undifferentiated retinal elements.
- Commonest primary intra ocular malignancy in children.
- Frequency 1:14,000 – 1:20,000 live births (Kenya – 1:17,000)
- 30 – 40% bilateral
- 94% sporadic, 6% familial.

Genetics

- Autosomal dominant gene on short arm of chromosome 13 at the Q 1,4 segment
- Germline mutation – transmissible, bilateral, multiple tumours
- Somatic – not transmissible, unilateral, solitary tumours
- Gene has incomplete penetrance

Familial retinoblastoma

Mean age at diagnosis

- Unilateral: 24 months (Kenya, 35 months)
- Bilateral: 12 months (Kenya; 26 months)
- 90% of cases diagnosed in under 3 years old
- rare in older children and adults

Signs and symptoms

Common:

- Leukocoria
- strabismus (squint)
- red eye
- Proptosis

Others:

- orbital cellulitis
- secondary glaucoma
- Hyphaema
- Nystagmus
- poor vision

Leucokoria

Leukocoria

Leukocoria

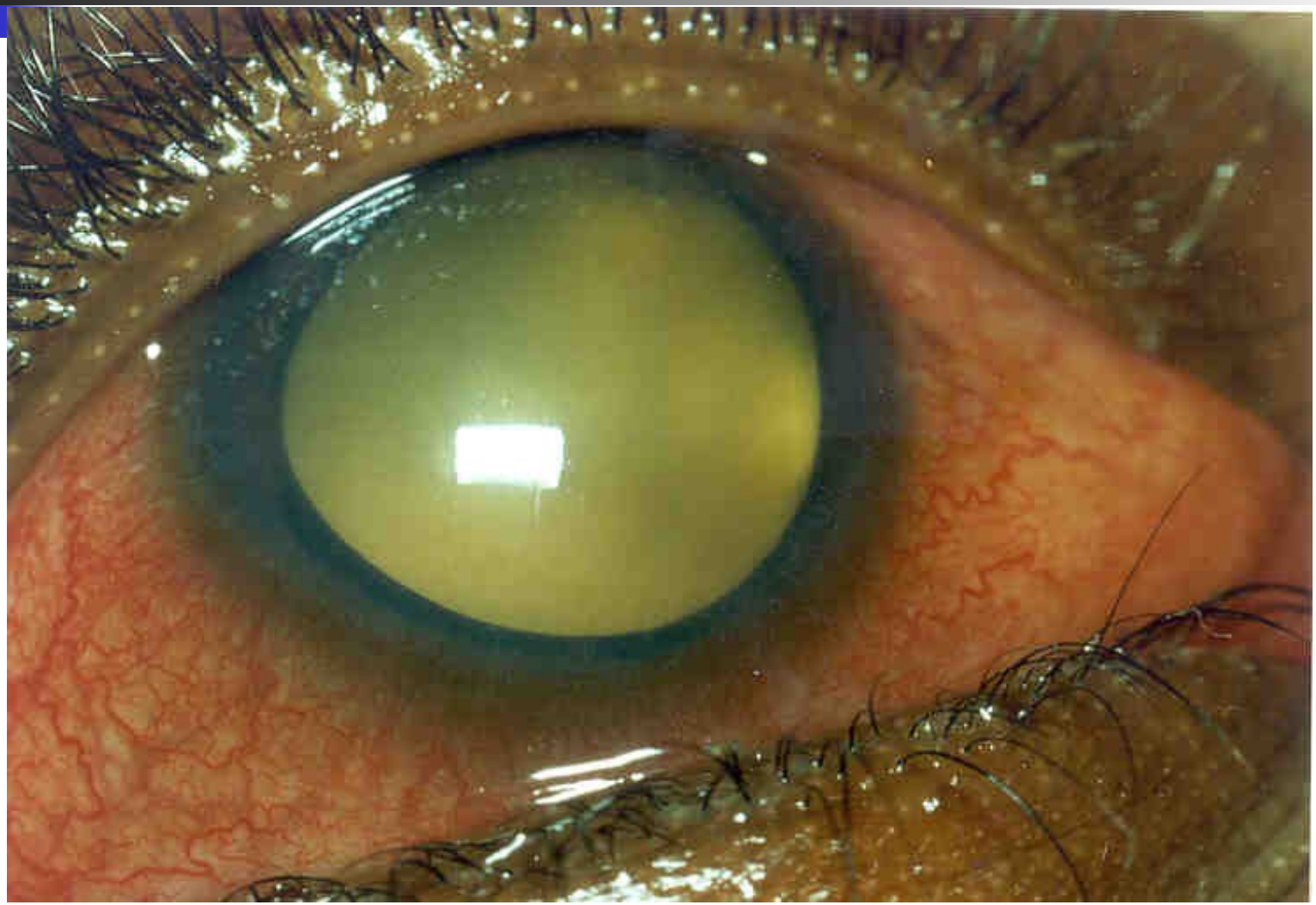

Hyphaema

Buphthalmos

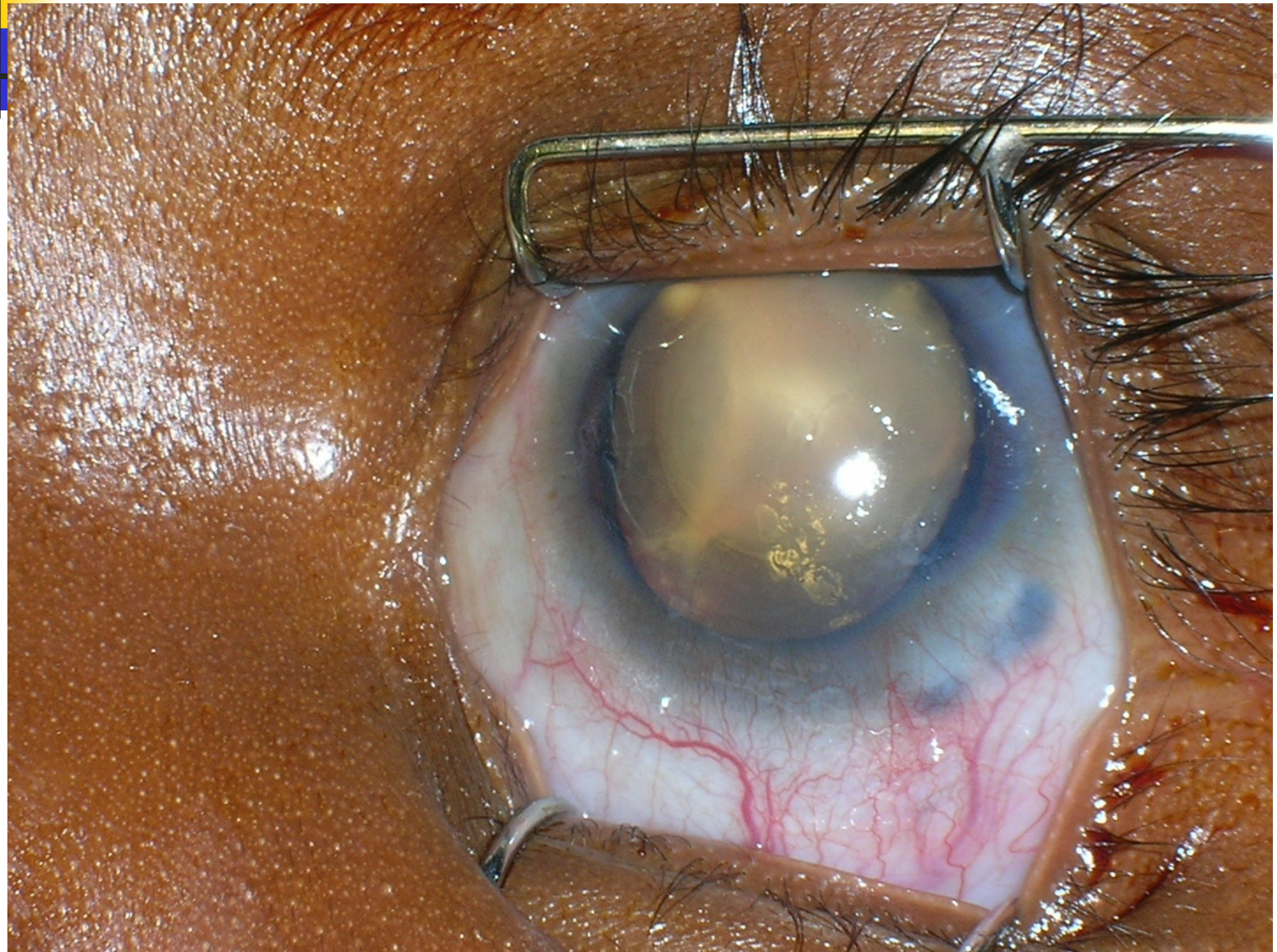

Orbital Cellulitis

Source: Singh BR, Luccheso M, Nicolau J, Silverberg M: Atlas of Pediatric Emergency Medicine: www.accessmedicinepediatrics.com
Copyright © The McGraw-Hill Companies, Inc. All rights reserved.

Proptosis

Proptosis

Differential diagnosis for leukocoria

- Cataract
- Retinopathy of prematurity (ROP)
- Persistent hyperplastic primary vitreous (PHPV)
- Organizing vitreous haemorrhage
- Toxocariasis
- Coat’s disease
- Endophthalmitis
- Coloboma of optic nerve or choroid

Investigations

- Ocular ultrasound
- Baseline: full haemogram, U&Es, LFTs
- CT scan
- MRI
- CSF cytology
- Bone marrow aspirate
- Histology
- Genetic studies

Ultrasound

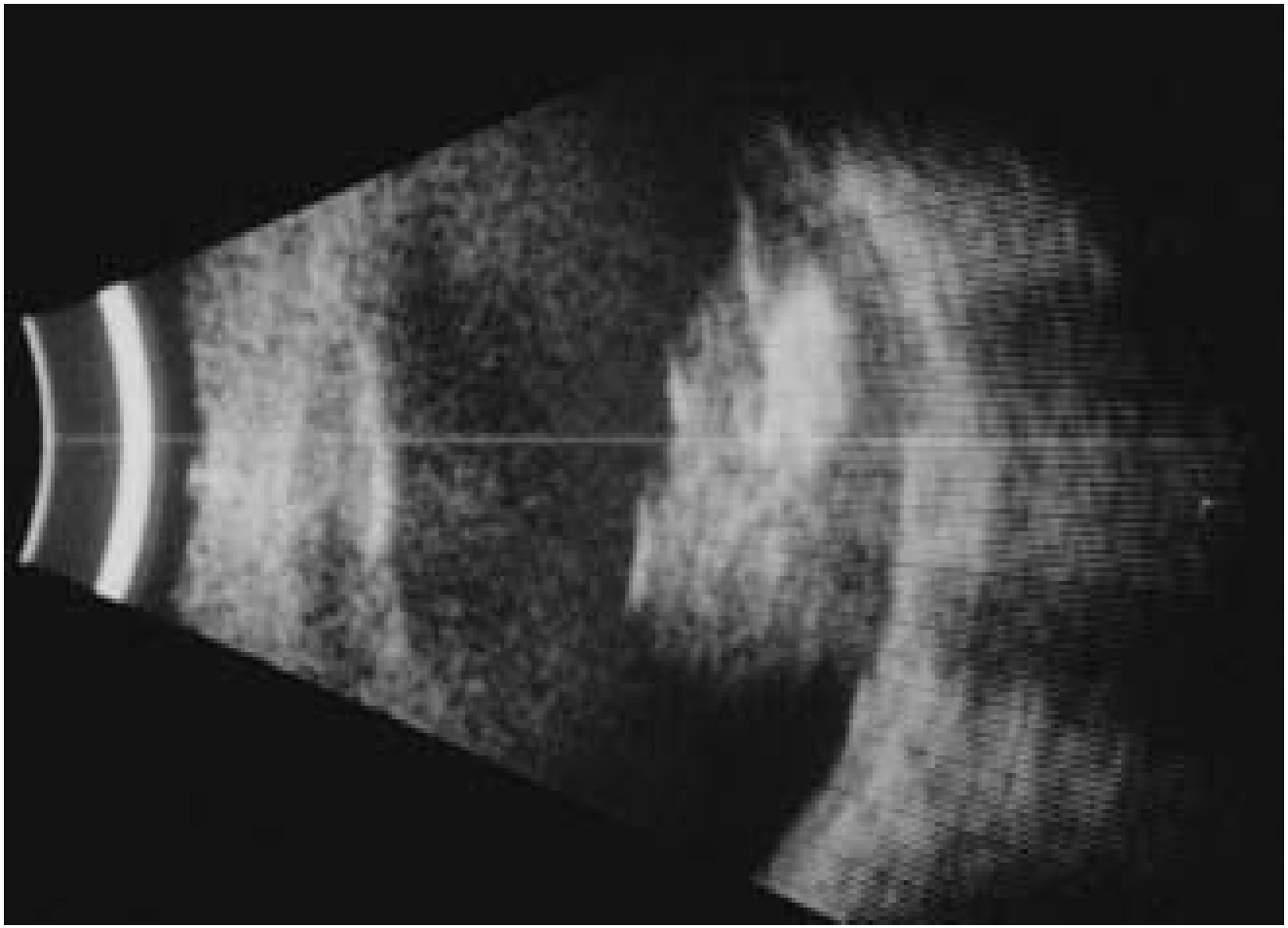

CT scan

Treatment

- Enucleation
- Laser photocoagulation
- Cryotherapy
- External beam radiation
- Brachy therapy
- Chemoreduction
- Systemic chemotherapy/radiotherapy

Chemoreduction

RE, 06/01/2015

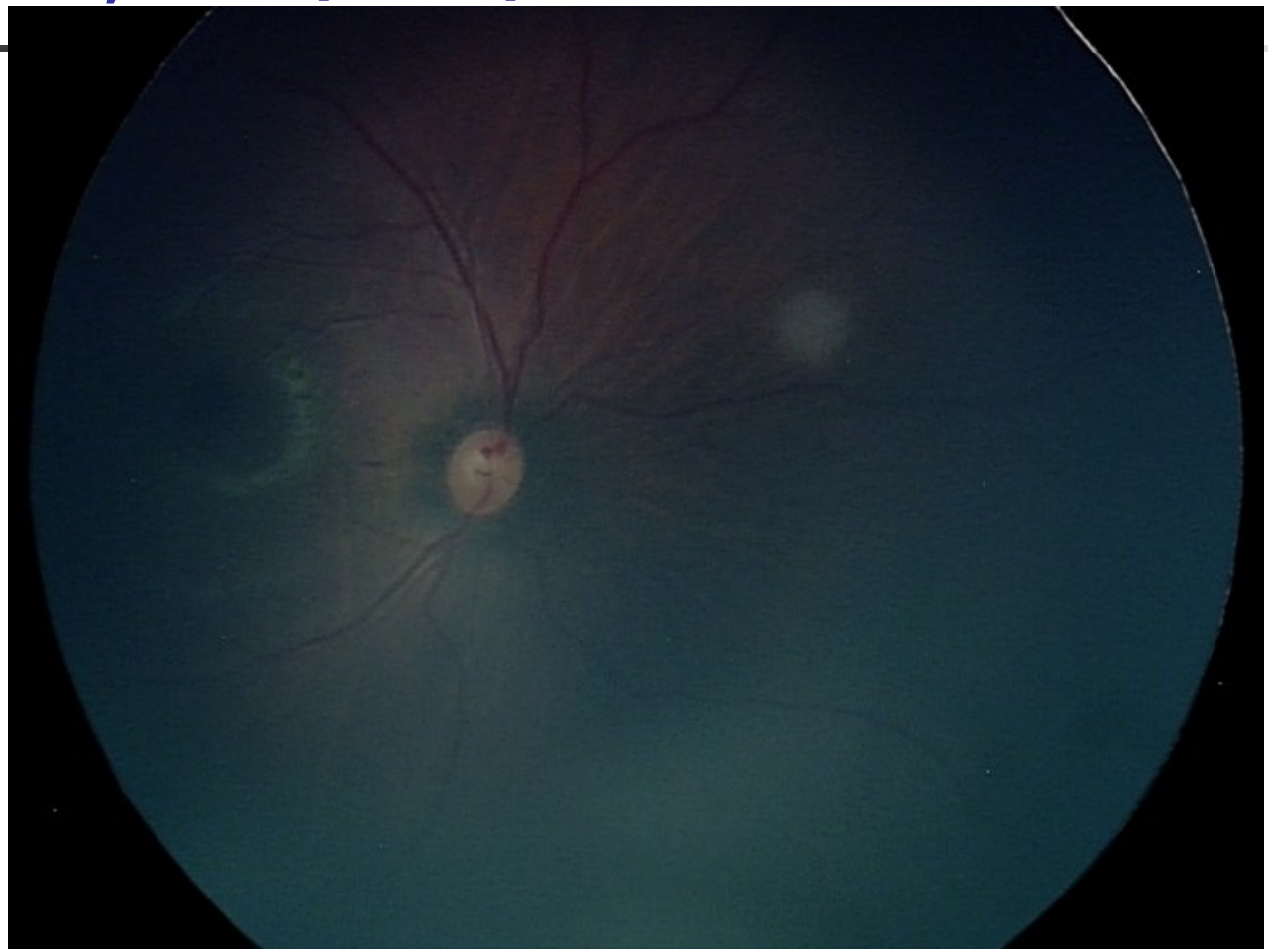

LE, 06/01/2015

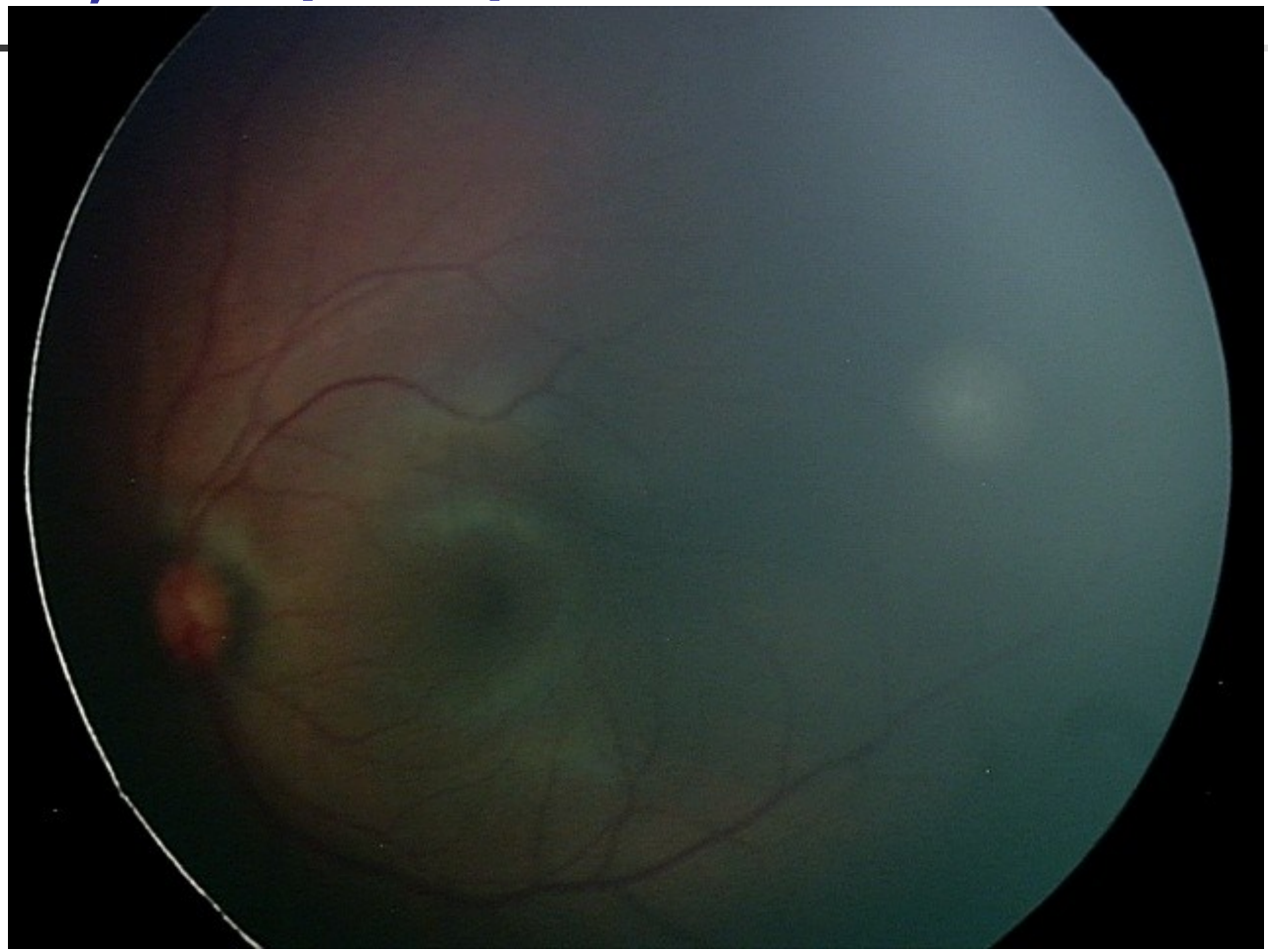

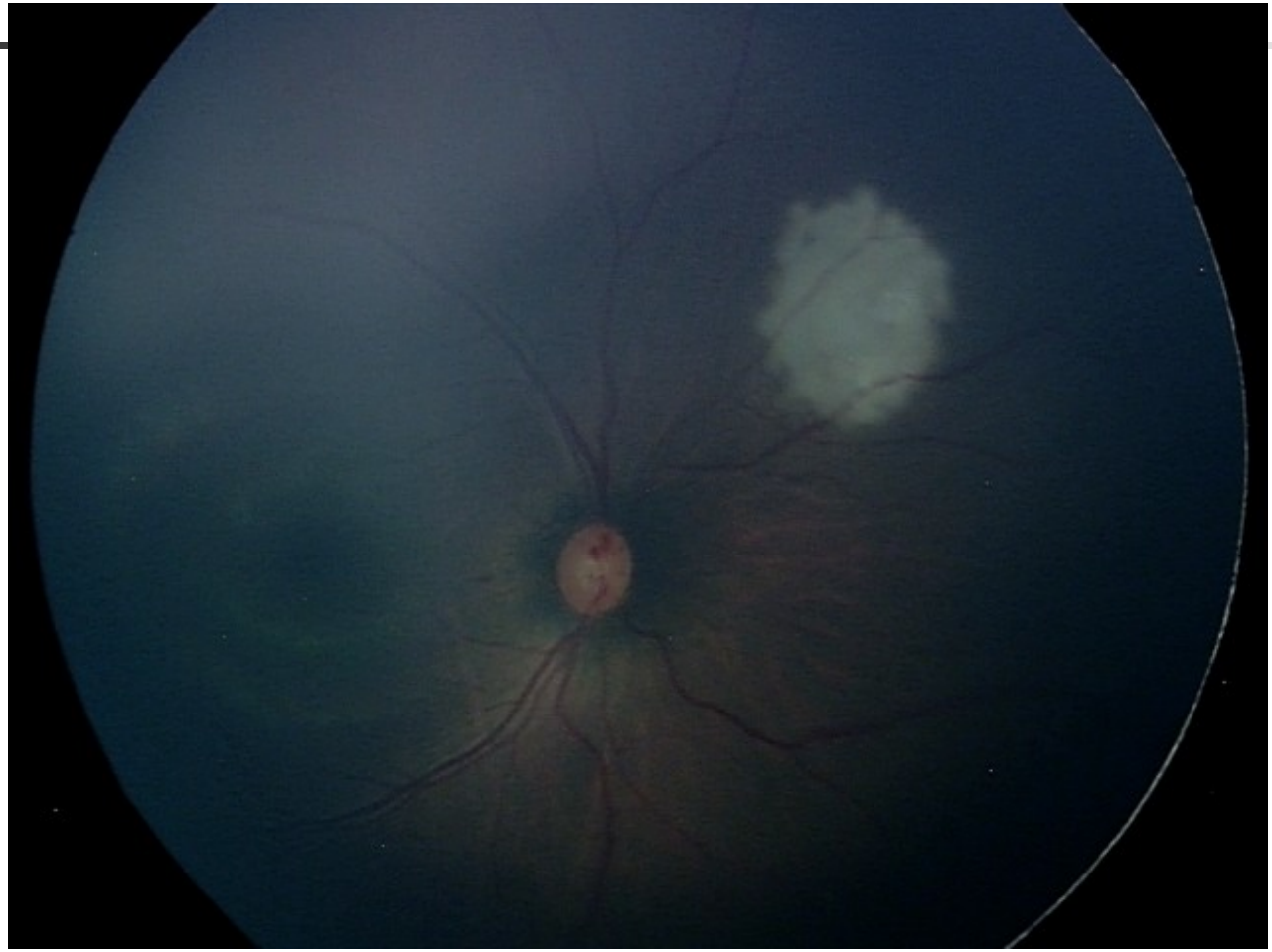

RE: 16/3/15

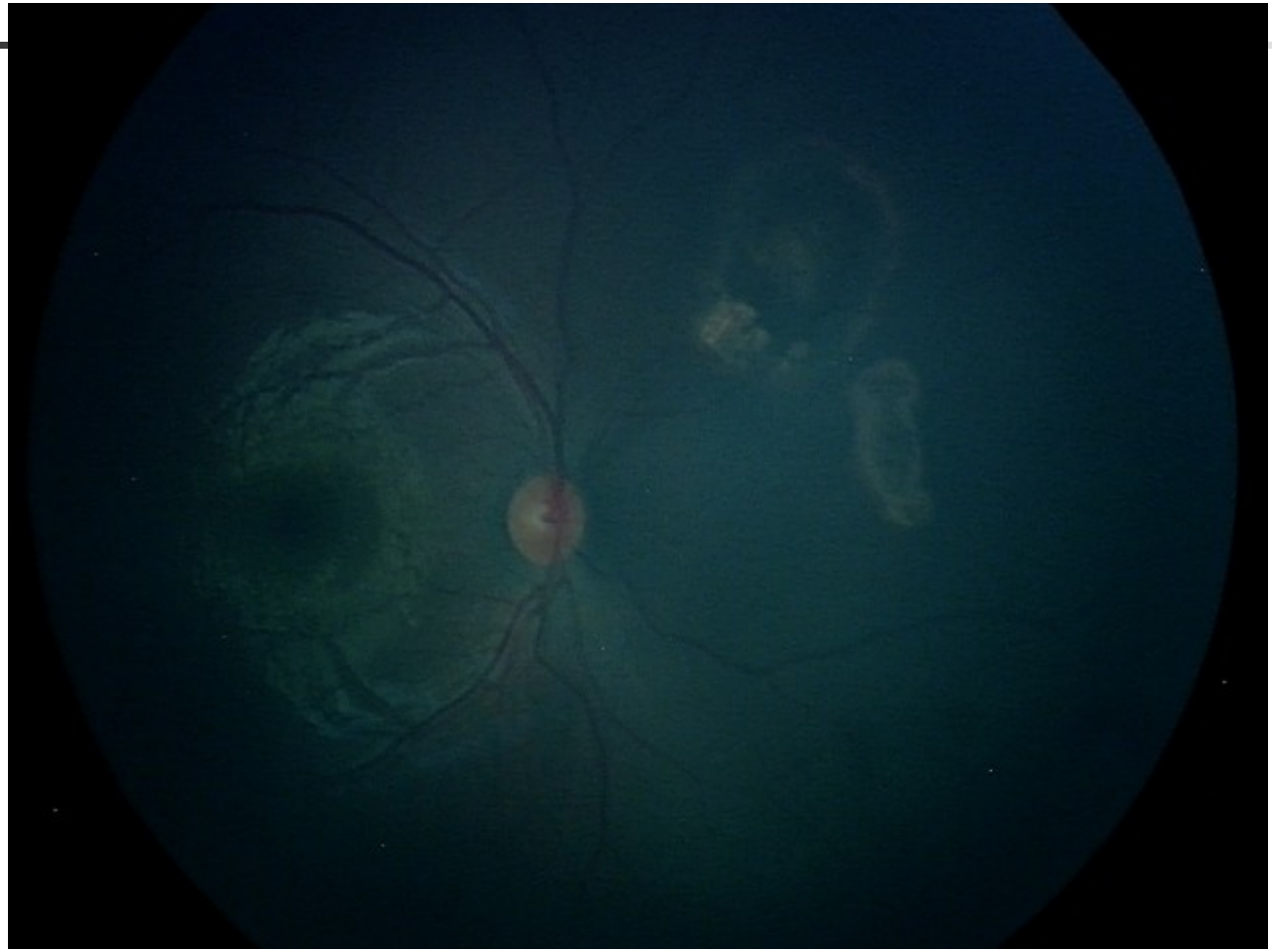

06/01/15

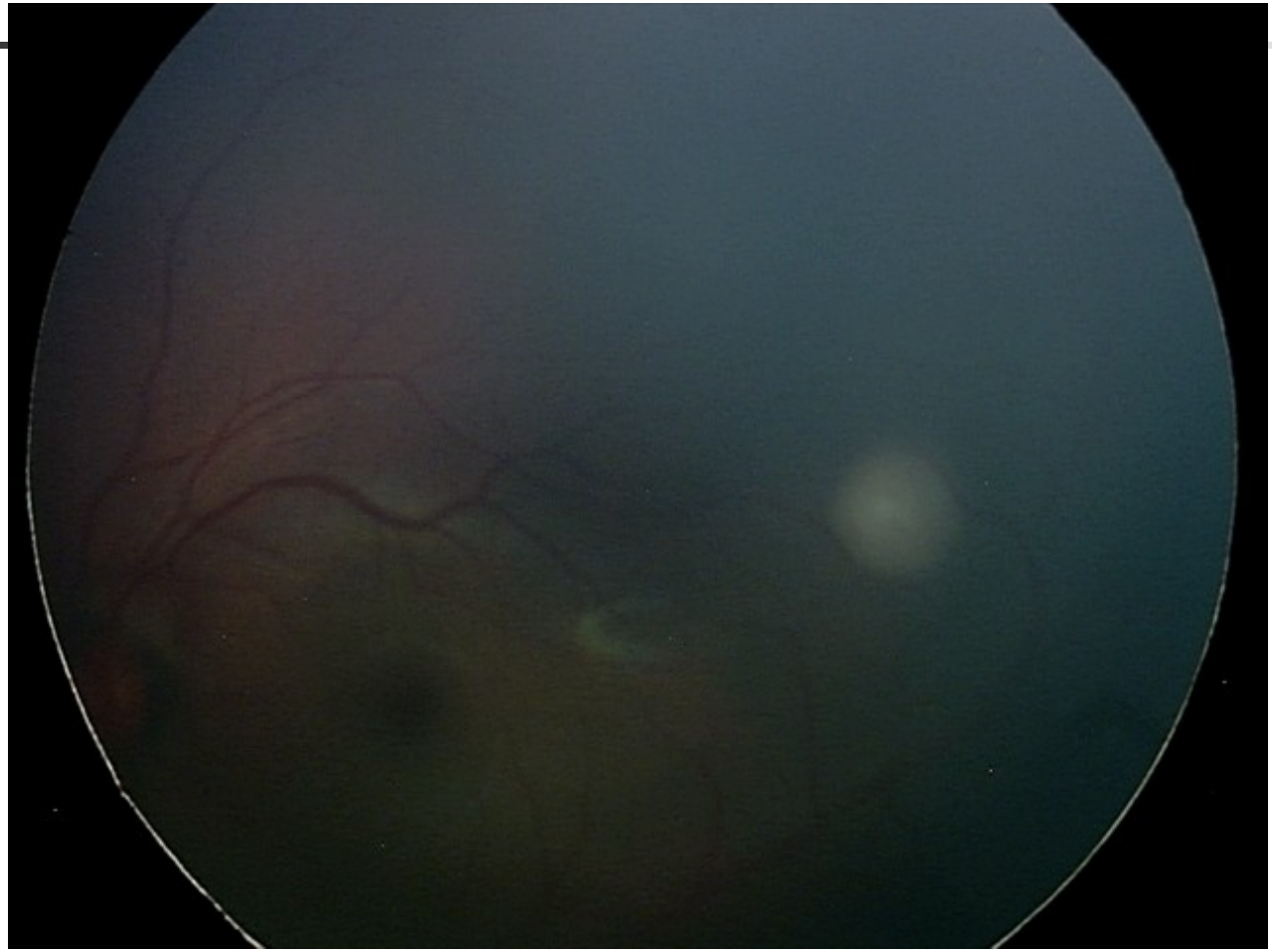

spread

- Optic nerve: intracranial
- Orbit
- Haematogenous: scalp, skull, long bones, abdominal viscera (lungs very rare)
- Lymphatic –Lymph nodes

Prognosis

Confined within eye ball; 95% survival with enucleation

In Kenya 3 year survival 26%

Risk factors for death:

- Delayed diagnosis and treatment
- Optic nerve, Scleral and choroidal involvement
- Proptosis

NB Bilateral retinoblastoma survivors; increased incidence of non ocular malignancies in later years. Avoid radiation.

Tone au alama nyeupe kwenye jicho la mtoto ni dalili ya Saratani (Cancer) ya macho.

Peleka mtoto kwa daktari wa macho haraka

Daisy's Eye Cancer Fund
A Global Response To Childhood Retinoblastoma

Ministry of Health
Division of Opthalmic services
Box 43319 Nairobi
Tel0202729876
Email:dops@health.go.ke

Rattansi Education Trust Building,University way
P.O.Box 63302-00619, Nairobi
Tel: 0720 729 936
Email: eafrica@daisyseyecancerfund.org
Website: www.daisyseyecancerfund.org

KENYAN NATIONAL RETINOBLASTOMA STRATEGY BEST PRACTICE GUIDELINES 2014

Daisy's Eye Cancer Fund - Kenya

Tel. +254 0719235621 or +254 0720229544
email: eafrica@daisyseyecancerfund.org
Website: www.daisyfund.org